

VESICO-UTERINE FISTULA FOLLOWING A CAESAREAN SECTION: A CASE STUDY.

Edson Willy Habimana^{a,*}, Richard Malumba^b, Ritah Bakesiima^{b,c}

^a*Department of Radiology, Ernest Cook Ultrasound Research and Education Institute, Kampala, Uganda.*

^b*Department of Research, Ernest Cook Ultrasound Research and Education Institute, Kampala, Uganda.*

^c*Department of Epidemiology and Biostatistics, Faculty of Public Health, Lira University, Uganda.*

Abstract

Background:

Vesico-uterine fistula refers to abnormal communication between the urinary bladder and the uterine cavity. It's among the obstetric fistulas which occur as part of the complications of medico-surgical procedures such as post-caesarian sections, and post-irradiation as in cancer treatment among others. About two million women worldwide have genital fistula with an annual incidence of 50,000 to 100,000 cases. In sub-Saharan Africa. an estimated 33,000 new fistula cases occur each year.

Case presentation:

This case study was of a 34-year-old female who came into the hospital complaining of long-standing abdominal pains associated with constant vaginal watery discharge, menstrual irregularities, painful sexual intercourse, and on-and-off urinary incontinence. All these started after a caesarian section was done one year ago. Her past Obstetric history revealed that she had ever had two vaginal deliveries and 1 caesarian section a year ago.

Results:

On ultrasonography, it was revealed that there was a defect in the continuity of the anterior wall of the uterus making a connection between the endometrial cavity and the urinary bladder. This was in line with the definition of a vesicouterine fistula.

Conclusion:

The report concluded that vesicouterine fistula is one of the genital urinary fistulae that can occur following a caesarian section and with increasing trends directly proportional to an increase in the incidence of caesarian sections.

Recommendation:

That every mother who has had a caesarian section should do a post-natal ultrasound at least within the first 6 months following the operation. This will help to identify potential genito-urinary fistulas earlier enough which can improve their overall management.

Keywords: Vesico-uterine, Fistula, Sonogram, Submitted: 2023-01-17 Accepted: 2023-02-01

1. Introduction

Vesico-uterine fistula is an abnormal communication between the urinary bladder and the uter-

ine cavity. It is among the genital urinary fistulae that include vesicovaginal, urethra-vaginal, and urethra-cutaneous among others (Majeed & Subhani, 2007). Urogenital fistulae are called so because they abnormally connect the urinary system and the genital system, about two million

*Corresponding author.

Email address: edsonwillyh@gmail.com (Edson Willy Habimana)

women worldwide have genital fistula with an annual incidence of 50,000 to 100,000 cases (Wall et al., 2005).

In sub-Saharan Africa, 33,000 new fistula cases occur each year and this high incidence may be attributed to obstetric care services being unavailable, inaccessible, underutilized, or of low quality (UNFPA, 2005). In addition, such abnormal communications are encountered after previous irradiation for pelvic malignancies and are most often located between the urinary bladder and vagina, however, in other population subgroups, the most frequently encountered fistulas are vesicouterine, especially in younger women with a previous history of pelvic surgical procedures (Ouedraogo et al., 2021).

In Uganda, the situation is not different from other parts of the world, the national prevalence of fistula is 2% among women aged 15–49 years and the prevalence is highest in the western region where one in 25 women has ever been affected. Furthermore, Barageine et al., (2014) in their study about risk factors for obstetric fistula in Western Uganda, concluded that surgeons contribute to a big proportion (25%) of fistula cases hence cesarean section being a risk factor in this region. Other factors highlighted included; prolonged labor, the weight of the baby of 3.5kg or more, the respondent's height of 150 cm or less (short stature), and low or no education risk factors for obstetric fistula in western Ugandan.

It is estimated that less than 5% of all urogenital fistulas are represented by vesicouterine fistulas. However, due to the increasing incidence of surgical procedures at the level of the pelvic area among young patients, suggested being a result of an increasing number of C-sections, the number of vesicouterine fistulas has reported an ascendant trend. In this respect, it should be noted that up to 88% of all these abnormal communications are related to C-sections (Machado, Machado, and Lourenço, 2018).

The presenting complaints of the patients depend upon the size and location of the fistula, although urinary incontinence is the commonest presenting complaint. Others include hematuria and amenorrhea, and lower abdominal pains., Ac-

ording to Abou-El-Ghar, El-Assmy, Refaie, and El-Diasty, (2012), precise assessment of uterovesical fistula is the mainstay of treatment where radiological investigations play a pivotal role in the evaluation of the size and location of the fistula. The investigations used to see for fistulous communications are cystography, hystero-graphy, ultrasound, CT scan with the sagittal reformation, and MRI pelvis.

Therefore, the current paper aims to report the case of a 34-year-old patient with a previous history of two vaginal births and one C-section, who was diagnosed with a vesicouterine fistula a year after the C-section.

2. Case

A 34-year-old female came into the Hospital complaining of long-standing abdominal pains associated with constant vaginal watery discharge, menstrual irregularities, painful sexual intercourse, and on-and-off urinary incontinence, all of which started after a caesarian section. Her past obstetric history revealed that she had ever had two vaginal deliveries and one caesarian section a year ago.

2.1. *On examination:*

Normal vital observations, there was tenderness on lower abdominal palpation, and a vaginal examination was done which revealed no abnormality.

2.2. *Patient's socio-economic history:*

She was married and blessed with two children, she had no formal job as she only had primary education, and she was a peasant with only a small retail shop to supplement her income.

2.3. *Investigations:*

Among other investigations, the attending doctor recommended a pelvic ultrasound scan.

2.4. *Ultrasound scan report for this client* **Preparations:**

The client was received in the radiology department, her request form was read well and she was prepared for the examination.

2.4.1. Preparations included;

Informing the patient about the examination to allay her anxiety She was then given two cups of water to first fill the urinary bladder. The patient was offered a health facility gown to change with her clothes during the examination. She was positioned supine for the transabdominal pelvic scan The abdomen was exposed and a warm gel was applied to her abdomen to expel air between the transducer and the abdomen. A low-frequency transducer was used (5.2 MHZ) for appropriate penetration to pelvic organs.

2.5. Ultrasound findings;

There was a defect in the continuity of the anterior wall of the uterus making a connection between the endometrial cavity and the urinary bladder.

The diameter of the canal measured 0.41 cm,

The endometrial cavity was filled with echo-free fluid which was similar across the canal and the urinary bladder.

There were no uterine masses observed.

The urinary bladder was well-filled, and its wall thickness was 4.0 cm

3. Discussion:

Normally the outline of the uterine wall should be intact and separate from the outline of the urinary bladder wall. However, as stated in the ultrasound findings, there was communication between the urinary bladder and the uterus. This is conclusive of a vesicouterine fistula, which is in line with the definition by Majeed & Subhani (2007), that a vesicouterine fistula is an abnormal communication between the urinary bladder and the uterine cavity.

Furthermore, the 34-year-old lady had a previous caesarian section which is believed to have put her at risk of developing this abnormal communication between the uterus and urinary bladder. This is in agreement with Machado, Machado, and Lourenço (2018) who found that vesicouterine fistulas are increasing due to the increasing incidence of surgical procedures at the level of the

pelvic area among young patients, especially due to the increasing number of C-sections.

The mother also had complaints of on-and-off urinary incontinence, irregular menstrual periods, lower abdominal pains, and watery vaginal discharge. These findings were similar to those from Abou-El-Ghar, El-Assmy, Refaie, and El-Diasty (2012) which portrayed that however much the presenting complaints of the patients depended upon the size and location of the fistula, they averagely included urinary incontinence, hematuria, amenorrhea, and lower abdominal pains.

The attending doctor requested an ultrasound scan which revealed a utero-vesical fistula. The ultrasound was mentioned also in a report by Abou-El-Ghar, El-Assmy, Refaie, and El-Diasty (2012) who established that radiological investigations play a pivotal role in the evaluation of the size and location of the fistula for precise treatment. They added that the investigations used to determine fistulous communications are cystography, hystero-graphy, ultrasound, CT scan with the sagittal reformation, and MRI pelvis.

4. Conclusion

Vesicouterine fistula is one of the genital urinary fistulae which has been a rare condition but because of the increase in the number of Caesarian sections, the prevalence of this form of the fistula is on the rise.

A person with vesicouterine fistula may present with lower abdominal pains, urinary incontinence, and menstrual irregularities among others.

Once suspected, an ultrasound is among the radiological investigations which can help in the diagnosis of the vesicouterine fistula. The other radiological investigations include cystography, hystero-graphy, and pelvic MRI among others.

5. Recommendations:

We recommend that every mother who has had a caesarian section should also do a post-natal ultrasound at least within the first 6 months following the operation. This will help to identify potential mothers with genito-urinary fistulas earlier

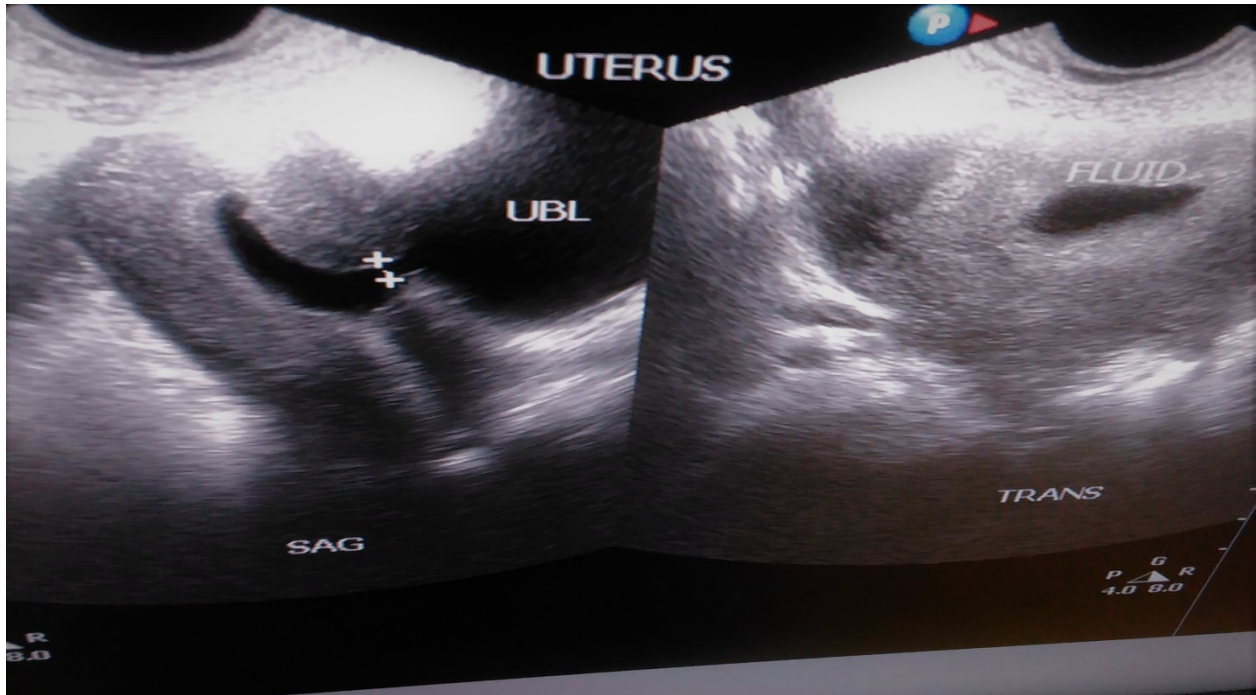


Figure 1: The sonogram showing the above findings

enough which can improve their overall management.

Health workers who receive post-caesarian section clients presenting with per vaginal watery discharge, urinary incontinence, menstrual irregularities, and lower abdominal pains, should suspect possible obstetric fistulas and so should request relevant radiological tests including ultrasound scan as a primary screening tool.

6. Acknowledgments:

Special thanks go to the Almighty God the giver of wisdom, to the management and staff of Double Cure Hospital my practicing ground, to ECUREI and her research department for their guidance, and to my friends Grace, David, Frank, Dr. Lydia and Deus who still remind me that I can do much more.

7. Funding:

This case report wasn't funded.

8. Ethics declarations:

When I developed an interest in this case, first I had to request a go-ahead from the management of Double Cure Hospital which was the case managing hospital where I was permitted, and thereafter, I requested the patient for publication of her case, however, I told her that there may be no direct benefits her but instead, the case is to add knowledge to the researchers and the general public where she voluntarily accepted with an agreement that I have not to disclose her specific particulars. A consent form was signed which is kept in the office of the hospital manager, the patient got also her copy.

February 16, 2023

9. Publisher details:

Publisher: Student's Journal of Health Research (SJHR)
(ISSN 2709-9997) Online
Category: Non-Governmental & Non-profit Organization
Email: studentsjournal2020@gmail.com
WhatsApp: +256775434261
Location: Wisdom Centre, P.O.BOX. 148, Uganda, East Africa.



10. References:

- 1) Abou-El-Ghar ME, El-Assmy AM, Refaie HF, El-Diasty TA. Radiological diagnosis of vesicouterine fistula: role of magnetic resonance imaging. *J Magn Reson Imaging* Aug 2012 Apr 25 2012;36(2):438-42 EpubPMID: 22535687. doi: 10.1002/jmri.23667 <https://doi.org/10.1002/jmri.23667>PMid:22535687
- 2) Barageine JK, Tumwesigye NM, Byamugisha JK, Almroth L, Faxelid E (2014) Risk Factors for Obstetric Fistula in Western Uganda: A Case Control <https://doi.org/10.1371/journal.pone.0112299>PMid:25401756 PMCID:PMC4234404 Study. *PLoS ONE* 9(11): e112299. doi:10.1371/journal.pone.0112299 <https://doi.org/10.1371/journal.pone.0112299>PMid:25401756 PMCID:PMC4234404
- 3) Machado Junior RA, Machado Junior LC and Lourenço LLE: Vesicouterine fistula (Youssef Syndrome): Case report and literature review. *Rev Bras Ginecol Obstet* 40(9): 563-569, 2018. PMID: 30231295. DOI: 10.1055/s-0038-1666998. <https://doi.org/10.1055/s-0038-1666998>PMid:30231295
- 4) Majeed SM, Subhani SS. An unusual case of Youssef's syndrome (vesicouterine fistula) and its relationship with placenta percreta. *J Coll Physicians Surg Pak* 2007;17(03):168-169
- 5) Ouedraogo B, Kirakoya B, Kabore M, Millogo A, Ouattara A and Kabore F: Vesicouterine fistula in Burkina Faso: Report of 36 cases in a multicentric study. *Société Internationale d'Urologie Journal* 2(4): 210-215, 2021. DOI: 10.48083/<https://doi.org/10.48083/NFMO2987> NFMO2987
- 6) Smayra T, Ghossain MA, Buy JN, Moukarzel M, Jacob D, Truc JB. Vesicouterine fistulas: imaging findings in three cases. *AJR Am J Roentgenol* Jan 2005;184(1):139-42 PMID:15615964. doi:10.2214/ajr.184.1.01840139. <https://doi.org/10.2214/ajr.184.1.01840139>PMid:15615964
- 7) Uganda Bureau of Statistics (UBOS) ICF International Inc (2012) Uganda Demographic and Health Survey 2011. Kampala, Uganda: UBOS and Calverton, Maryland: ICF International Inc.
- 8) Goh JWT, Krause HG, editors (2004) Female Genital tract fistulae: Brisbane: University of Queensland Press.
- 9) UNFPA (2005) The Campaign to End Fistula. Annual Report.
- 10) Wall LL, Arrowsmith SD, Briggs ND, Browning A, Lassey A (2005) The Obstetric Vesicovaginal Fistula in the Developing World. *Obstetrics & Gynecology Survey* 60: S3-S47. <https://doi.org/10.1097/00006254-200507001-00002>PMid:16034313

Author biography

Edson Willy Habimana is a student at the Department of Radiology, Ernest Cook Ultrasound Research and Education Institute, Kampala, Uganda.

Richard Malumba is a lecturer at the Department of Research, Ernest Cook Ultrasound Research and Education Institute, Kampala, Uganda.

Ritah Bakesiima is a lecturer at the Department of Research, Ernest Cook Ultrasound Research and Education Institute, Kampala,

Uganda, and at the department of Epidemiology and Biostatistics, Faculty of Public Health, Lira University, Uganda.