

A PROSPECTIVE OBSERVATIONAL STUDY ON TOTAL KNEE REPLACEMENT OUTCOMES IN OSTEOARTHRITIC KNEES WITH VARUS DEFORMITY.

Ch Ramesh Babu¹, Banna Kiran Kumar^{2*}, Kiran Kumar Joshi³, Pradeep Kumar A Sale⁴, Manoj Kumar⁴

¹Assistant Professor, Department of Orthopaedics, Gandhi Medical College and Gandhi Hospital, Musheerabad, Padmarao Nagar, Secunderabad, Telangana, India.

²Associate Professor, Department of Orthopaedics, Gandhi Medical College and Gandhi Hospital, Musheerabad, Padmarao Nagar, Secunderabad, Telangana, India.

³Assistant Professor, Department of Orthopaedics, Govt. Medical College Sangareddy, Tadlapalle, Sangareddy, Telangana, India.

⁴Postgraduate Resident, Department of Orthopaedics, Gandhi Medical College and Gandhi Hospital, Musheerabad, Padmarao Nagar, Secunderabad, Telangana, India.

Abstract

Background

Osteoarthritis (OA) of the knee with varus deformity is a common degenerative condition that severely impacts mobility and quality of life. Total Knee Arthroplasty (TKA) is the standard surgical treatment for end-stage OA, though varus correction poses technical challenges.

Objectives

To evaluate the clinical, functional, and radiological outcomes of TKA using a posterior cruciate substituting prosthesis in patients with varus knee deformity.

Methods

This prospective observational study included 30 patients (mean age: 63.2 years; 70% female) with primary OA and varus deformity (Kellgren–Lawrence grades III and IV), who underwent TKA at Mahatma Gandhi Memorial Hospital, Warangal. Clinical and functional status were assessed using the Knee Society Score (KSS), while radiological evaluation confirmed prosthetic alignment. Follow-ups were performed at 6 weeks, 3 months, 6 months, and 1 year.

Results

The mean preoperative clinical KSS (56.4) improved significantly to 90.2 postoperatively ($p < 0.01$), and the functional score improved from 48.3 to 81.6 ($p < 0.01$). Radiographs showed that all patients achieved neutral mechanical alignment without signs of implant loosening. By 6 weeks, over 80% of patients reported substantial pain relief, restored range of motion, and improved stair-climbing ability. No intraoperative or postoperative complications, such as infection or DVT, were reported. Outcomes were favorable across all deformity severity groups ($<10^\circ$, $10\text{--}20^\circ$, $>20^\circ$).

Conclusion

TKA using posterior cruciate substituting prostheses provides significant functional and radiological improvements in osteoarthritic knees with varus deformity. Proper preoperative planning and surgical precision are key to optimal outcomes.

Recommendations

Preoperative assessment should emphasize deformity severity and soft tissue balance. Surgeons should adopt individualized soft tissue release techniques and confirm mechanical axis restoration intraoperatively. Long-term follow-up and larger sample studies are recommended to assess prosthesis survivorship and late complications.

Keywords: Osteoarthritis knee, varus deformity, total knee arthroplasty, Knee Society Score, functional recovery.

Submitted: 2025-02-21

Accepted: 2025-03-28

Published: 2025-03-31

Corresponding Author: Dr. Banna Kiran Kumar,

Email: drbkk3025@gmail.com

Associate Professor, Orthopaedic Department, Gandhi Medical College & Gandhi Hospital Musheerabad, Padmarao Nagar, Secunderabad, Telangana, India.

Introduction

Osteoarthritis (OA) of the knee is a progressive, degenerative joint disease and one of the leading causes of disability worldwide, particularly in the aging population. It is characterized by the gradual breakdown of articular cartilage, subchondral bone changes, osteophyte formation, synovial inflammation, and narrowing of the joint space. As the disease advances, patients experience chronic pain, restricted mobility, joint stiffness, deformity, and a significant decline in quality of life. The increasing life expectancy and sedentary lifestyle trends have contributed to a sharp rise in the global burden of osteoarthritis [1, 2]. Among the various types of deformities associated with advanced knee osteoarthritis, varus deformity is the most frequently encountered. It involves the inward angulation of the knee joint in the coronal plane, often resulting from progressive medial compartment cartilage loss [3]. Varus alignment often results in disproportionate stress on the knee joint, particularly increasing the load on the medial tibiofemoral compartment, which accelerates its degenerative changes. This deformity is not merely a bony misalignment; it is often accompanied by complex soft tissue adaptations, including contracture of the medial structures and laxity of the lateral collateral ligament complex, further complicating surgical correction [4]. Total Knee Arthroplasty (TKA) has emerged as the gold standard surgical intervention for end-stage osteoarthritis of the knee, especially in cases unresponsive to pharmacological or conservative therapy. The goal of TKA is to relieve pain, restore joint function, and correct deformity, thereby enabling patients to regain mobility and lead an independent life. Over the decades, significant advancements in prosthesis design, surgical instrumentation, and perioperative care have made TKA a highly successful and reproducible procedure [3, 4]. Among various implant designs, posterior cruciate substituting prostheses are frequently employed in knees with varus deformities, as they offer improved stability and facilitate better kinematic restoration. However, performing TKA in knees with significant varus deformity poses considerable surgical challenges. Achieving optimal component alignment, joint line restoration, and proper soft tissue balancing is critical to ensure implant longevity and favorable outcomes. Improper correction of the deformity or inadequate soft tissue management may lead to residual malalignment, instability, implant loosening, or early failure. Therefore, a comprehensive evaluation of preoperative deformity, intraoperative decision-making, and postoperative functional outcomes is imperative [5-9]. This prospective observational study aims to contribute valuable clinical evidence on the effectiveness of Total Knee Arthroplasty (TKA) in managing osteoarthritic knees with varus deformity. By analyzing clinical, functional, and radiological outcomes using standardized assessment

tools such as the Knee Society Score (KSS), the study seeks to enhance understanding of patient recovery trajectories and the impact of deformity severity on postoperative outcomes. The findings are intended to guide orthopedic surgeons in refining surgical planning, soft tissue balancing, and prosthesis alignment techniques to optimize patient care and functional recovery in complex varus knees.

MATERIALS AND METHODS

Study Design and Setting

This study employed a **prospective cohort design** to evaluate the clinical, functional, and radiological outcomes of Total Knee Arthroplasty (TKA) in patients with primary osteoarthritis (OA) of the knee with varus deformity. The study was conducted at **Mahatma Gandhi Memorial Hospital (MGMH), Warangal**, a tertiary care teaching hospital affiliated with Kakatiya Medical College, Telangana. The hospital serves as a major referral center in the region, offering a high volume of orthopedic procedures, including joint replacements. The study was carried out over two years, from **September 2022 to August 2024**, within the Department of Orthopaedics.

Patient Selection Criteria

The study included patients aged between 50 and 70 years who were diagnosed with primary osteoarthritis of the knee with varus deformity (Kellgren–Lawrence grades III and IV) [5-9]. Both male and female patients were included, provided they were medically fit to undergo surgery and consented to participate. Patients with inflammatory arthritis such as rheumatoid arthritis, valgus deformity, active infection, history of high tibial osteotomy, neuropathic joints, or skin conditions affecting the surgical field were excluded.

Sample Size

A total of **30 patients** were enrolled in the study. The sample size was determined based on **feasibility**, expected patient load during the study period, and existing literature on similar studies evaluating TKA in varus-deformed knees. Published prospective studies in comparable settings have used sample sizes ranging between 25 and 40 patients to effectively assess functional and radiological outcomes. Given the homogeneity of the study population and the use of standardized surgical and rehabilitation protocols, a sample of 30 patients was considered sufficient to detect meaningful changes in outcome measures. The sample also allowed for subgroup analysis based on varus deformity severity ($<10^\circ$, $10\text{--}20^\circ$, $>20^\circ$), thereby enabling comparative evaluation without compromising statistical validity.

Preoperative Assessment

All patients underwent a comprehensive preoperative evaluation including detailed history taking, clinical examination, and functional assessment using the Knee Society Score (KSS), which includes both clinical and functional components [3, 6]. Preoperative radiological investigations included standing anteroposterior and lateral views of the knee and full-length sonograms to assess the extent of deformity, joint space narrowing, and bone quality. The range of motion, fixed deformities, and soft tissue status were also recorded.

Surgical Technique

All surgical procedures were performed by the same orthopedic surgical team using a standardized operative technique. Under spinal or regional anesthesia, patients were positioned supine with the knee at 90 degrees of flexion. A midline anterior incision followed by a medial parapatellar arthrotomy was used to access the joint. Posterior cruciate substituting total condylar prostheses were used in all cases. Bony cuts were made using intramedullary and extramedullary alignment guides, and appropriate soft tissue releases were performed to correct deformity and achieve balanced gaps in extension and flexion. Femoral and tibial components were fixed using polymethylmethacrylate (PMMA) bone cement. Patellar denervation was performed, but patellar resurfacing was not routinely done. Trial components were used to check alignment, stability, and patellofemoral tracking before final implantation. Hemostasis was achieved, and the wound was closed in layers with a sterile compressive dressing.

Postoperative Protocol

Postoperatively, the knee was immobilized using a knee immobilizer and compressive bandage. Intravenous antibiotics were administered for the first 48 hours, followed by oral antibiotics for five days. Deep vein thrombosis (DVT) prophylaxis was provided with low molecular weight heparin for five days. On the first postoperative day, patients were encouraged to begin static quadriceps exercises. Full weight-bearing ambulation was initiated from the second postoperative day using a walker, depending on the patient's tolerance. Active knee flexion and dynamic quadriceps exercises were started on the fourth day. Sutures were removed on the tenth postoperative day, and patients were advised to continue physiotherapy and follow-up at 6 weeks, 3 months, 6 months, and 1 year post-surgery.

Outcome Measures

The primary outcome measures were the Knee Society Clinical Score and Functional Score assessed preoperatively and postoperatively at each follow-up.

These scores provided an objective evaluation of pain, stability, range of motion, walking ability, and stair-climbing capacity. Radiological outcomes were evaluated using the Knee Society Radiographic Evaluation and Scoring System. Standardized anteroposterior and lateral radiographs were used to assess tibiofemoral alignment, component positioning, radiolucent lines, and evidence of loosening or osteolysis. Radiographic zones were carefully scrutinized for progression of radiolucency or prosthetic subsidence.

Bias

To minimize potential sources of bias, all surgical procedures were performed by the same experienced orthopedic team using a standardized operative protocol. Preoperative and postoperative assessments were conducted using validated scoring systems (KSS) by independent assessors blinded to the surgical team. Patients were selected based on strict inclusion and exclusion criteria to ensure homogeneity. Consistent follow-up intervals and uniform physiotherapy protocols were maintained across all participants to reduce performance and detection bias throughout the study period.

Ethical Considerations

Prior to the commencement of the study, ethical approval was obtained from the Institutional Ethics Committee (IEC) of Kakatiya Medical College, Warangal (Approval Number # KIEC/PG DISS-2021-22/94). All participants provided written informed consent after being informed in detail about the nature of the study, the surgical procedure, potential risks, and follow-up requirements. The study was conducted by the ethical standards outlined in the Declaration of Helsinki. The confidentiality and privacy of all participants were strictly maintained throughout the study.

Statistical Analysis

All data were recorded in Microsoft Excel and analyzed using statistical software. Descriptive statistics such as mean, standard deviation, and percentages were calculated. The paired t-test was used to compare preoperative and postoperative scores within groups, while analysis of variance (ANOVA) was used for intergroup comparisons based on deformity severity. A p-value less than 0.05 was considered statistically significant.

Results:

Participant Flow and Recruitment

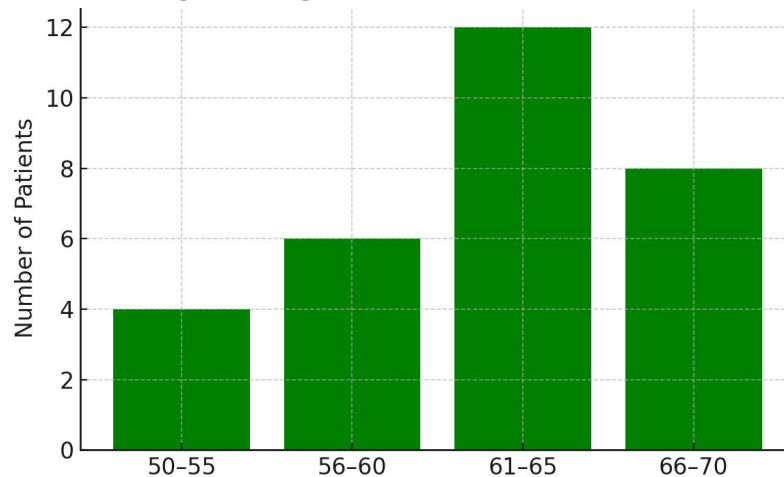
A total of **42 patients** were assessed for eligibility for this study between September 2022 and August 2024 at Mahatma Gandhi Memorial Hospital, Warangal. Of these: 6 patients were excluded: 3 had valgus deformity, 2 were diagnosed with inflammatory arthritis, and 1 had a history

of high tibial osteotomy. **36 patients** met the inclusion criteria. **30 patients** provided written informed consent and were enrolled in the study. All 30 underwent Total Knee Arthroplasty (TKA) and were included in the final analysis. **No participants were lost to follow-up** during the 1-year observation period.

Age Distribution

The study included patients aged between **50 and 70 years**, which aligns with the commonly affected age group for degenerative osteoarthritis. The **mean age** was approximately **63.2 years**. The age distribution is shown in Figure 1.

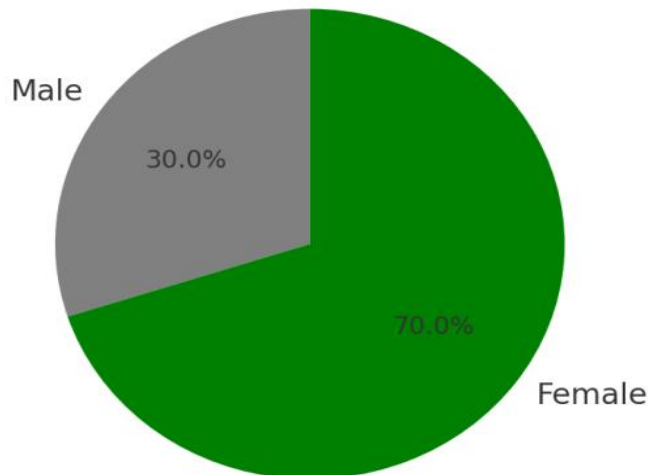
Figure 1: Age Distribution of Patients



Gender Distribution

There were **21 females (70%)** and **9 males (30%)**, indicating a higher prevalence of symptomatic osteoarthritis among women, as reported in existing literature (Figure 2).

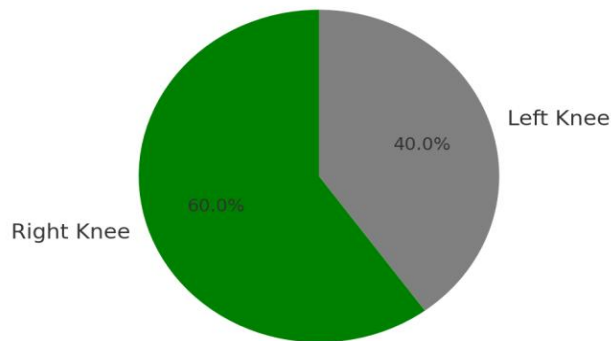
Figure 2: Gender Distribution of the Patients



Side Distribution

In this study, **60%** of patients had **right-sided** knee involvement, while the remaining **40%** had **left-sided** pathology. No bilateral procedures were performed during the study (Figure 3).

Figure 3: Side of Surgery Distribution



Clinical and Functional Outcome Analysis

The evaluation of clinical and functional improvement in this study was based on the Knee Society Score (KSS), which is divided into two distinct components: the Knee Clinical Score, which assesses parameters such as pain, range of motion (ROM), stability, and fixed deformities; and the Knee Functional Score, which evaluates the patient's ability to walk and climb stairs. Each of these scores is interpreted using a standard grading scale, where a score between 85 and 100 is considered excellent, 70 to 84 as good, 60 to 69 as fair, and any score below 60 as

poor. This scoring system provides a comprehensive and objective assessment of both the anatomical and functional outcomes following TKA.

A. Knee Clinical Score – Preoperative vs Postoperative

The mean preoperative clinical score was 56.4, indicating poor to fair knee function. After surgery, the mean postoperative clinical score significantly improved to 90.2 (Table 1).

Table 1: Preoperative vs Postoperative Knee Clinical Score

Score Grade	Preoperative (No. of Patients)	Postoperative (No. of Patients)
Excellent (85–100)	0	21
Good (70–84)	4	9
Fair (60–69)	10	0
Poor (<60)	16	0
Total	30	30

The improvement in clinical score was statistically significant ($p < 0.01$), indicating that TKA provided consistent relief from pain and improved mobility and stability.

B. Knee Functional Score – Preoperative vs Postoperative

The mean functional score increased from 48.3 preoperatively to 81.6 postoperatively. This reflects a substantial improvement in patients' ability to walk and climb stairs (Table 2).

Table 2: Preoperative vs Postoperative Knee Functional Score

Score Grade	Preoperative (No. of Patients)	Postoperative (No. of Patients)
Excellent (85–100)	0	16
Good (70–84)	5	13
Fair (60–69)	9	1
Poor (<60)	16	0
Total	30	30

Page | 6

Patients who were previously house-bound or needed assistive devices were able to ambulate independently and climb stairs postoperatively.

Table 3: Follow-Up Outcome Analysis at Different Time Intervals

Follow-Up Interval	Clinical KSS (Mean \pm SD)	Functional KSS (Mean \pm SD)	Key Improvements Observed
6 weeks	75.6 \pm 6.2	69.4 \pm 7.1	Pain reduction, independent ambulation
3 months	83.1 \pm 5.4	75.8 \pm 6.3	Improved range of motion and walking endurance
6 months	88.3 \pm 4.7	79.2 \pm 6.0	Stair-climbing regained, stable joint function
1 year	90.2 \pm 4.3	81.6 \pm 5.8	Full functional independence, pain-free mobility

Postoperative follow-up was conducted at 6 weeks, 3 months, 6 months, and 1 year. At each interval, clinical and functional progress were recorded using the Knee Society Clinical Score (KSS) and Functional Score. The improvement was progressive and statistically significant at each time point.

All time-point improvements were statistically significant when compared to preoperative scores ($p < 0.01$). No deterioration in function was noted at any interval.

Radiological Outcome

Radiological outcomes were evaluated through postoperative radiographs, which were specifically assessed for tibiofemoral alignment, the positioning of prosthetic components, and the presence of any radiolucent lines or signs of prosthesis loosening. All patients in the study demonstrated **neutral mechanical alignment** postoperatively, indicating accurate surgical correction of varus deformity. Importantly, there were **no cases of radiographic loosening or component malalignment** observed during the 12-month follow-up period, suggesting satisfactory implant fixation and stability throughout the study duration.

Complications

There were no intraoperative complications encountered during any of the procedures, such as fractures or tendon ruptures. Postoperative complications were also minimal,

with no reported cases of wound infection, deep vein thrombosis (DVT), or prosthetic loosening. Furthermore, all patients achieved complete wound healing within 10 days of surgery, indicating good surgical technique, appropriate postoperative care, and favorable patient recovery profiles.

Discussion

Osteoarthritis of the knee is a common degenerative joint condition, particularly affecting the elderly, and is frequently associated with pain, structural deformity, and significant functional impairment. The presence of varus deformity in advanced osteoarthritis further disrupts normal knee biomechanics and poses challenges to alignment and load distribution. Total Knee Arthroplasty (TKA) has become a definitive and widely accepted treatment for end-stage knee osteoarthritis, aiming to alleviate pain, correct deformity, and enhance joint function.

In the present prospective study, a notable female predominance (70%) was observed, with the highest incidence in the age group of 61–65 years. This demographic pattern corresponds with global trends that indicate a higher prevalence of osteoarthritis in postmenopausal women, potentially due to hormonal changes, reduced bone density, and diminished muscle support.

Baseline evaluations revealed poor clinical and functional Knee Society Scores (KSS), with means of 56.4 and 48.3, respectively, indicating substantial preoperative disability. Following TKA, both scores improved significantly to 90.2 and 81.6. This improvement underscores the effectiveness of TKA in alleviating symptoms, enhancing joint motion, and improving overall quality of life. More than 70% of patients achieved "Excellent" postoperative scores, with no individuals remaining in the "Poor" category.

These outcomes are consistent with existing literature reporting similar improvements following TKA using various prosthetic systems [10–16]. The scores obtained in this study fall within the "Excellent" range of the Knee Society classification (85–100 points), further validating the procedure's efficacy.

The postoperative radiographic evaluation confirmed the restoration of neutral mechanical alignment in all patients, which is essential for implant longevity and functional durability, as emphasized in previous research [17–19]. No radiographic signs of malalignment or prosthetic loosening were observed at the one-year follow-up, reflecting precise surgical execution and proper component positioning.

Furthermore, the study reported no intraoperative complications such as fractures, tendon injury, or neurovascular damage. Postoperative complications were minimal, with all patients achieving timely wound healing and no instances of infection, deep vein thrombosis, or implant failure. These favorable outcomes can be attributed to thorough preoperative planning, standardized surgical techniques, and a structured rehabilitation protocol.

Generalizability

The findings of this study apply primarily to patients aged 50–70 years with advanced primary osteoarthritis and varus deformity undergoing TKA in tertiary care settings. As all surgeries were performed by a single orthopedic team using a standardized protocol, results may not fully represent diverse surgical practices. However, the inclusion of varied deformity severities enhances relevance. Further multicenter studies with larger, more diverse populations are needed to improve the generalizability and external validity of these findings.

Conclusions

This prospective study demonstrates that TKA using a posterior cruciate substituting prosthesis is a highly effective surgical intervention for patients with advanced osteoarthritis of the knee associated with varus deformity. The procedure resulted in a statistically and clinically significant improvement in both Knee Society Clinical and Functional Scores, reflecting enhanced joint stability, mobility, and pain relief.

Radiological evaluations confirmed proper prosthetic alignment, and no evidence of loosening or malpositioning was observed during the follow-up period. Importantly, the

procedure was associated with a low rate of complications, and all patients showed excellent postoperative recovery and wound healing.

Thus, TKA not only restores anatomical alignment and joint function but also substantially improves the quality of life, functional independence, and mobility of patients suffering from degenerative knee pathology. With appropriate surgical technique, patient selection, and rehabilitation, TKA remains the gold standard treatment for end-stage knee osteoarthritis with varus deformity.

Limitations

When compared to similar national and international studies, the outcomes observed in this cohort reaffirm the efficacy of TKA in managing osteoarthritic knees with varus deformity. However, the study does acknowledge limitations, including a relatively small sample size and a limited follow-up duration of one year. Longer-term follow-up would be essential to assess implant survivorship, late complications, and sustained functional gains.

Recommendations

Recommendations for improving outcomes in Total Knee Arthroplasty for osteoarthritic knees with varus deformity include performing thorough preoperative evaluations to assess deformity severity, optimizing soft tissue balancing techniques, and ensuring precise alignment during surgery. Additionally, long-term follow-up and larger studies are essential to validate the findings and improve patient care.

List of abbreviations

AP – Anteroposterior
BMI – Body Mass Index
DVT – Deep Vein Thrombosis
KSS – Knee Society Score
OA – Osteoarthritis
PMMA – Polymethylmethacrylate
ROM – Range of Motion
TKA – Total Knee Arthroplasty

Source of funding

The study had no funding.

Conflict of interest

The authors declare no conflict of interest.

Acknowledgements:

First and foremost, I express my deepest gratitude to Dr. S. Lakshmi Narayana, Professor, Department of Orthopaedics, Kakatiya Medical College, Warangal, for his invaluable guidance, support, and mentorship throughout this study. His clinical expertise and academic vision have been instrumental in shaping this work. I extend my heartfelt thanks to the teaching faculty and postgraduates of the

Department of Orthopaedics, Kakatiya Medical College, for their constant encouragement, practical assistance, and constructive feedback during this research. I am also sincerely thankful to the management and staff of Mahatma Gandhi Memorial Hospital, Warangal, for providing the infrastructure and facilities necessary to carry out this study efficiently. Special thanks to all the patients who consented to be part of this study. Their cooperation and willingness to participate in follow-up evaluations made this research possible.

Author contributions

CHRB- Concept and design of the study, results interpretation, review of the literature, and preparing the first draft of the manuscript. Statistical analysis and interpretation, revision of the manuscript. **BKK- Concept** and design of the study, results interpretation, review of the literature, and preparing the first draft of the manuscript, revision of the manuscript. **KKJ-Review** of literature and preparing the first draft of the manuscript. Statistical analysis and interpretation. **PKAS- Concept** and design of the study, results interpretation, review of the literature, and preparing the first draft of the manuscript. Statistical analysis and interpretation, revision of the manuscript. **MK-Concept** and design of the study, results interpretation, review of the literature, and preparing the first draft of the manuscript.

Data availability

Data Available

Author Biography

Dr. Ch Ramesh Babu is a dedicated orthopedic surgeon and Assistant Professor at Gandhi Medical College, Secunderabad, Telangana. He completed his undergraduate medical education (MBBS) and MS in Orthopaedics. He is currently undergoing advanced clinical training in orthopedic surgery, with interests in trauma care, joint reconstruction, and minimally invasive techniques.

Dr. B Kiran Kumar is a dedicated orthopedic surgeon and Associate Professor at Kakatiya Medical College (KMC), Warangal, Telangana, with significant expertise in trauma care, arthroplasty, and orthopedic education. He completed his MBBS at KMC, Warangal (1998–2003), and subsequently served as a Civil Assistant Surgeon at MPHC, Bhopal Bhupalpally, from 2008 to 2012, gaining valuable clinical experience in primary healthcare and orthopedic practice. Pursuing his passion for orthopedics, he obtained his MS in Orthopaedics from KMC under Dr. NTR University of Health Sciences, Vijayawada (2012–2015), further honing his surgical skills and understanding of musculoskeletal disorders. Throughout his career, Dr. Kiran Kumar has performed numerous complex trauma surgeries and total knee replacement procedures,

demonstrating proficiency in managing critical orthopedic cases and improving patient outcomes. In addition to his clinical work, he has contributed significantly to medical education by teaching undergraduate and postgraduate students, focusing on non-traumatic orthopedics, clinical examination techniques, and diagnostic skills. Actively involved in seminars, workshops, and CME programs, including TOSACON 2018 and events organized by the Warangal Orthopaedic Society, he remains committed to academic excellence and ongoing professional development. In recognition of his contributions, he was promoted to Associate Professor of Orthopaedics at KMC in August 2023, where he continues to advance orthopedic care and education. ORCID: <https://orcid.org/0009-0008-5476-538X>.

Dr. Kiran Kumar Joshi is a dedicated orthopedic surgeon and Assistant Professor at Gandhi Medical College, Secunderabad, Telangana. He completed his undergraduate medical education (MBBS) and MS in Orthopaedics. He is currently undergoing advanced clinical training in orthopedic surgery, with interests in trauma care, joint reconstruction, and minimally invasive techniques.

Dr. Pradeep Kumar A Sale is a second-year postgraduate resident in the Department of Orthopaedics at Gandhi Medical College, Secunderabad, Telangana. He completed his MBBS from Shimoga Institute of Medical Sciences, Shivamogga, Karnataka, in the 2016–2022 batch. He is currently undergoing advanced clinical training in orthopedic surgery, with interests in trauma care, joint reconstruction, and minimally invasive techniques. ORCID: <https://orcid.org/0009-0005-9368-9381>.

Dr. Manoj Kumar A is currently a final-year postgraduate resident in the Department of Orthopaedics at Gandhi Medical College, Secunderabad, Telangana. He completed his undergraduate medical education (MBBS) from ACSR Government Medical College, Nellore, Andhra Pradesh, as part of the 2015–2021 batch. With a strong academic foundation and clinical training, Dr. Manoj Kumar is pursuing advanced orthopedic surgical training with a focus on trauma, joint disorders, and musculoskeletal rehabilitation. His clinical interests include joint preservation techniques, orthopedic biomechanics, and evidence-based management of musculoskeletal conditions. <https://orcid.org/0009-0000-9642-7161>

References:

1. Vail TP, Lang JE. Insall and Scott had surgery on the knee. 4th ed. Philadelphia: Churchill Livingstone, Elsevier; 2006. p. 1455-1521.
2. Insall J, Ranawat CS, Scott WN, Walker P. Total condylar knee replacement. Preliminary report. Clin Orthop Relat Res 1976;120:149-54. <https://doi.org/10.1097/00003086-197610000-00023>

3. Kim RH, Scott WN. Operative techniques: total knee replacement. Philadelphia: Saunders-Elsevier 2009. p. 91-103. <https://doi.org/10.1016/B978-1-4160-4984-5.50012-7>
4. Bijlsma JW, Berenbaum F, Laffey FP. Osteoarthritis: an update with relevance for clinical practice. *Lancet*; 2011 Jun 18;377:2115-26. [https://doi.org/10.1016/S0140-6736\(11\)60243-2](https://doi.org/10.1016/S0140-6736(11)60243-2)
5. John N Insall, Lawrence D Dorr, Richard D Scott, W. Norman Scott. Rationale of The Knee Society Clinical Rating System. *Clin Orthop* 1989 Nov;248:13-14. <https://doi.org/10.1097/00003086-198911000-00004>
6. Stuart MJ. Anatomy and surgical approaches in Joint replacement arthroplasty. 3rd ed. 2003. p. 945.
7. Kettlekamp DB, Pryor P, Brady TA. Selective use of the variable axis knee. *Clin Orthop Relat Res* 1979;3:301-2.
8. Frankel VH, Burstein AH. Orthopaedic Biomechanics. The Application of Engineering to the Musculoskeletal System. Philadelphia: Lea and Febiger; 1970. p. 24-8.
9. Berger RA, Rubash HE, Seel MJ, Thompson WH, Crossett LS. Determining the rotational alignment of the femoral component in total knee arthroplasty using the epicondylar axis. *Clin Orthop Relat Res* 1993;286:40-7. <https://doi.org/10.1097/00003086-199301000-00008>
10. Rodriguez JA, Bhende H, Ranawat CS. Ranawat Orthopaedic Center, New York, NY 10021, USA Total condylar knee replacement: A 20-year follow-up study. *Clin Orthop Relat Res* 2001;(388):10-7. <https://doi.org/10.1097/00003086-200107000-00004>
11. Martin SD, McManus JL, Scott RD, Thornhill TS. Press-fit condylar total knee arthroplasty. 5- to 9-year follow-up evaluation. *J Arthroplasty*. 1997 Sep;12(6):603-14. [https://doi.org/10.1016/S0883-5403\(97\)90132-7](https://doi.org/10.1016/S0883-5403(97)90132-7)
12. Clayton RAE, Amin A et al., Five-Year follow-up of the PFC Sigma Total Knee Arthroplasty *J Bone J OInt Surg Br*; 88:SUPP II, 2006 <https://doi.org/10.1016/j.knee.2006.06.003>
13. Asif S, Choon DSK. Mid-Term results of Cemented Press-Fit Condylar Sigma Total Knee Arthroplasty System, *Journal of Orthopaedic Surgery* 2005;13(3):280-4 <https://doi.org/10.1177/230949900501300311>
14. Alemparte J, Cabezas A, Azocar O, Hernandez R, Acevedo M. Midterm results of an AGC total knee arthroplasty system survival and function analysis: 2 to 8 years follow --up results. *J Arthroplasty* 2003;18:420-5. [https://doi.org/10.1016/S0883-5403\(03\)00017-2](https://doi.org/10.1016/S0883-5403(03)00017-2)
15. Buehler KO, Venn - Waston E, D" Lima DD, Colwell CW Jr. The press fit condylar total knee system: 8 to 10-year results with a posterior cruciate-retaining design *J Arthroplasty* 2000;15:698-701. <https://doi.org/10.1054/arth.2000.8189>
16. Dixon MC, Brown RR, et al. Modular Fixed Bearing Total Knee Arthroplasty with Retention of Posterior Cruciate Ligament. *J Bone Joint Surg. Am* 2005;87:598. <https://doi.org/10.2106/JBJS.C.00591>
17. Insall JN, Hood RW, Flawn LB, Sullivan DJ. The total condylar knee prosthesis in gonarthrosis: A five to nine-year follow-up of the first one hundred consecutive replacements. *J Bone Joint Surg Am* 1983;65:619. <https://doi.org/10.2106/00004623-198365050-00006>
18. Rand JA, Trousdale RT, Ilstrup DM, Harmsen WS. Factors affecting the durability of primary total knee prostheses. *J Bone Joint Surg Am*. 2003;85:259-265. <https://doi.org/10.2106/00004623-200302000-00012>
19. Scott DF, Smith RR. A prospective, randomized comparison of posterior stabilized versus cruciate-substituting total knee arthroplasty: a preliminary report with minimum 2-year results. *J Arthroplasty*. 2014;29:179 181. doi: 10.1016/j.arth.2014.03.050. <https://doi.org/10.1016/j.arth.2014.03.050>

PUBLISHER DETAILS:

Page | 10

Student's Journal of Health Research (SJHR)

(ISSN 2709-9997) Online

(ISSN 3006-1059) Print

Category: Non-Governmental & Non-profit Organization

Email: studentsjournal2020@gmail.com

WhatsApp: +256 775 434 261

**Location: Scholar's Summit Nakigalala, P. O. Box 701432,
Entebbe Uganda, East Africa**

